
DATE PRESENTING CLINICAL SIGNS

History: Intermittent vomiting past month. Progressed from 2-3 times weekly to daily. Previous AUS 7/12/18.

PATIENT Labs: 1/11/20- CBC/Chem 10 NSF.

ULTRASONOGRAPHIC EXAMINATION OF THE ABDOMEN
SPECIES
Urinary System

Feline

The urinary bladder, trigone, and pelvic urethra are normal in thickness and the mucosal surface is smooth. The bladder lumen is moderately distended. A small amount of suspended echogenic debris is observed within the lumen. No masses, inflammatory changes or calculi are observed. Ureteral papillae are normal.

BREED

Persian

The left kidney is normal in size. The left kidney revealed normal shape and architecture with smooth peripheral margins. There is slight loss of corticomedullary distinction. There is no evidence of pyelectasia, nephroliths or hydronephrosis.

SEX

Neutered Male

The right kidney is normal size at 4.31 cm in length. The right kidney revealed normal shape and architecture with smooth peripheral margins. There is mild loss of corticomedullary distinction. There is no evidence of pyelectasia, nephroliths or hydronephrosis.

AGE

2013

Adrenal Glands
INTERPRETED BY

The left adrenal gland is normal in size at 0.47 cm. The left adrenal gland has normal shape; homogenous parenchyma. The phrenic vasculature, glandular echogenicity and detail are unremarkable. Capsule, cortex, and medullary definition are normal.

Andrea Nicastro, DVM,
Diplomate ACVIM
(Small Animal
Internal Medicine)

The right adrenal gland is normal in size at 0.38 cm. The right adrenal gland has normal shape; homogenous parenchyma. The phrenic vasculature, glandular echogenicity and detail are unremarkable. Capsule, cortex, and medullary definition are normal.

HOSPITAL NAME
Spleen

The spleen is normal in size with a normal capsular contour. There is appropriate echogenicity and echotexture. No focal lesions are observed. Splenic vasculature is normal.

REFERRING VET
Liver
INVOICE

The liver is subjectively normal in size with normal contours and structure. There is appropriate echogenicity and echotexture. No overt structural evidence of inflammatory, infiltrative or regenerative pathology is evident. Vascular and biliary tracts are of normal volume with no evidence of congestion. No pathological hepatic lymphadenopathy observed.

The gallbladder lumen is moderately distended. The wall is thin and smooth. Luminal contents are anechoic. The cystic and common bile ducts are normal.

Gastrointestinal

The gastric lumen is not distended. The fundic portion of stomach is of normal wall thickness with a normal layering pattern. In the region of the gastric outflow tract, the wall becomes thickened (up to 0.65 cm) and irregular with a loss of mural detail circumferentially. The wall thickening appears to normalize at the level of the proximal duodenum. The remainder of the intestinal tract appears normal in terms of wall thickness (0.17 – 0.23 cm) with slight disruption of the normal 1:3 muscularis/mucosal ratio.

Pancreas

The pancreas is not definitively visualized; however, there are no obvious abnormalities observed in this region.

Free Abdomen

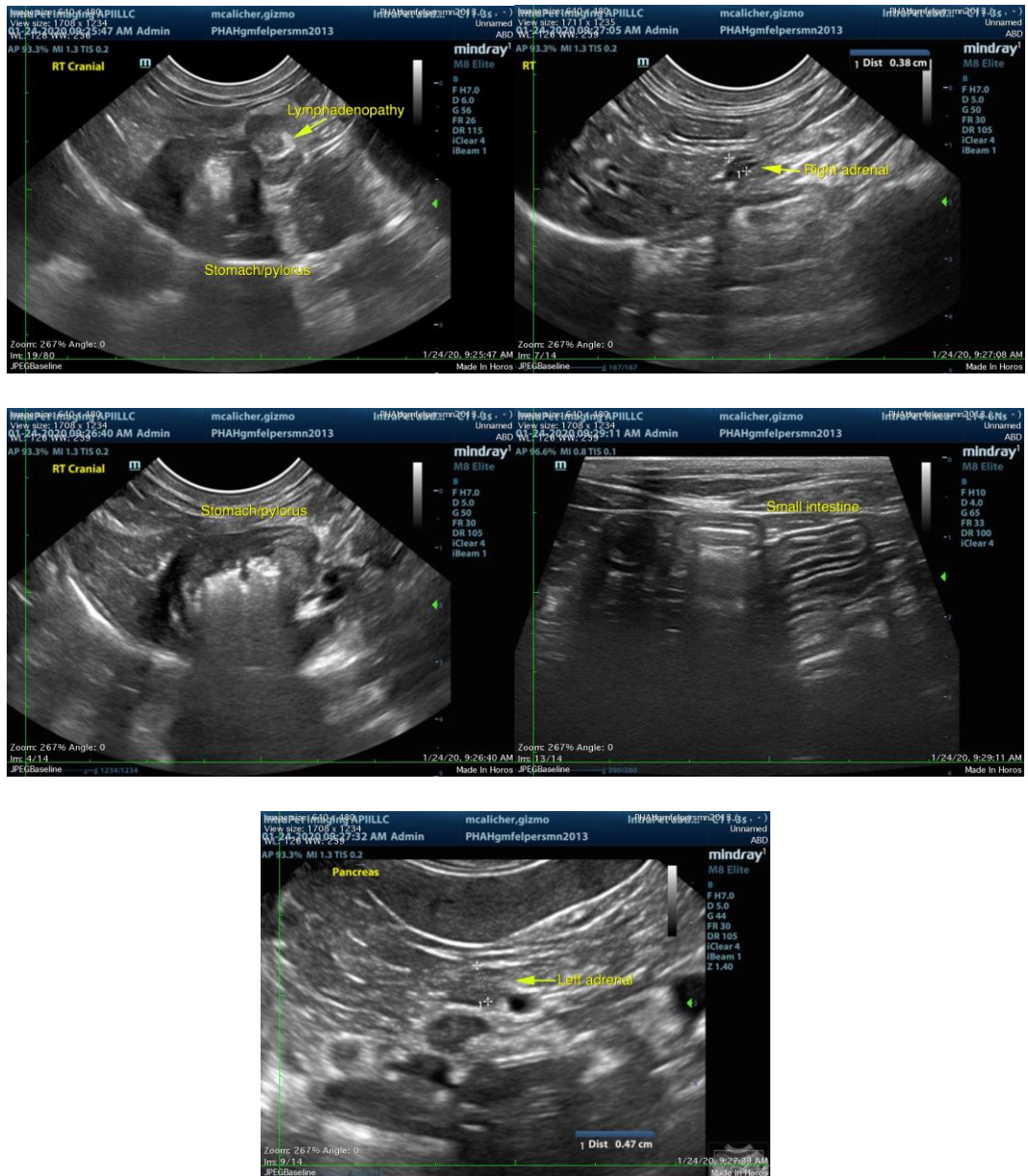
Two enlarged, irregular, hypoechoic lymph nodes are observed adjacent to the pylorus. These are thought to be the pancreaticoduodenal lymph nodes. They are surrounded by hyperechoic mesentery.

ULTRASONOGRAPHIC FINDINGS

- The abnormal wall thickening in the region of the gastric outflow tract is most concerning for neoplastic infiltration i.e. lymphoma, adenocarcinoma. Pyogranulomatous disease is also a differential, but considered less likely.
- The adjacent lymphadenopathy is also concerning for neoplastic infiltration, although reactive change cannot be excluded.
- The prominent muscularis layer of the small intestine is most consistent with inflammatory disease, although a normal variant is also possible.
- Mild loss of corticomedullary distinction in both kidneys could be consistent with chronic degenerative disease or interstitial nephritis.
- The echogenic debris in the urinary bladder lumen could be consistent with cells, crystals, and/or mucus.

INTERPRETATION OF THE FINDINGS & FURTHER RECOMMENDATIONS

Fine needle aspirate of the abnormal gastric wall and adjacent lymph nodes is recommended. Surgical biopsy may be necessary to get a definitive diagnosis if cytological evaluation is inconclusive. Three view thoracic radiographs are recommended to assess for metastatic disease.



The information and recommendations provided are based on the images presented by the referring veterinarian. No evaluation can be communicated regarding pathology that was not visible in the image/video clips provided.

Thank you for this referral. If the clinical or image interpretation does not parallel your findings or if I can be of any further assistance please contact me.

Andrea Nicastro, DVM, Diplomate ACVIM (*Small Animal Internal Medicine*)
andrea_nicastro2@hotmail.com